
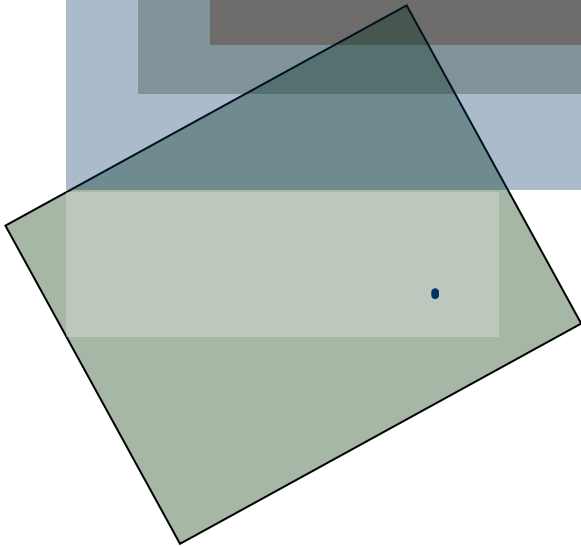


Paralytic Hand



تموز/2006

.()

.() excursion

(- -)

Medical Research) **MRC**

: , (Council

M₀

M₁

M₂

M₃

M₄

M₅

Tendon Tunneler

. sarcomers

: excursion

4-3

: _____

moment arm

(torque- moment)

)

(

(

)

(°57.3 =)

()

()

)

()

: _____

%100

%50)

%100

.(

/ /

.()

(-)

:

.(())

()

:Trick movement

lateral squeeze pinch

)
()

()

.(

web

.C

()

(- -)

2-1

2-1

2-1

3:

18,

()

: 3

Riordan

=

=

:
:
:

()

--

:

. C7

C8 C5

()

10

. ()

4.5)

)

. (4

. (

. ()

()

arachade of frohse

-
-
-
-
-
-
-
-
-
-

:

, segmental

, axonotmesis () neuropraxia

(,)

%77

neurotmesis

axonotmesis neuropraxia

. %15-2

%92

4-3

4-1

4-3

4-3

()

15

/ 1

/ 1

-
-
-
-
-
-

()

Standard (FCU transfer) :

()

(

)

(A2-A1)

()

_____*

()

-
-
-
-

)

(

Boyes _____

Chapman

()

)

(

°0

°45

°90

°45

)

3

3-2

(

°20

A2-A1

Table 56.1. Muscles Innervated by the Median Nerve

<i>Muscle</i>	<i>Function</i>
Flexor Carpi Radialis (FCR)	Wrist Flexion
Palmaris Longus (PL)	Wrist Flexion
Pronator Teres (PT)	Forearm Pronation
Pronator Quadratus (PQ)	Forearm Pronation
Flexor Digitorum Superficialis (FDS)	PIP Flexion
Flexor Digitorum Profundus (FDP)	PIP and DIP Flexion
Flexor Pollicis Longus (FPL)	IP Thumb Flexion
Abductor Pollicis Brevis (APB)	Thumb Palmar Abduction, Pronation
Opponens Pollicis (OP)	Thumb Pronation
Flexor Pollicis Brevis (FPB)	Thumb MP Flexion

)

(

, III – II

(– – –)

Keyboard

-
- -
 -
 -

)

()

)

(

.(

)

:

- .1
- .2
- .3
- .4
- .5

()

:

-
- Z plasty •
-
-
-
-
-

()

)

°15

(

.(°20)

.()

()

•

•

•

•

•

(°20

-

- °30

)

4

•

•

)

10-5

•

(

•

•

•

(

-

)

•

•

•

•

(A2-A1)

•

:

-
-
-
-
-
-
-

:

:

.()

- -

:

, (reverse) metacarpal arch

.()

.()

:

.()

()

.() ,

)

(

-

.()

- -)

(

:

()

•

.()

()

•

()

•

()

.(Stiles-Bunnell)

.()

)

.(

(Zancolli-Brocks)

: _____

()

()

.(pinch)

•

•

: pinch _____

°30

()

. pinch

, ()

key pinch

: _____

(trick movement)

Bunnell

Brand

.(Riordan)

)

.(

Fowler

)
(
-
Zancolli

(Lasso operation)

, Lasso

:

: Fowler

Riordan

: _____

Fowler

: _____

:

Fowler

:

: Zancolli

Zancolli

°40

°20 -

°30 -

°45

+

°30

:

:

•

•

•

5-4

Fowler

Fowler

Riordan

Fowler

:

grip

pinch

(Froment's sign)

(jeanne's sign)

•

•

•

•

(

pinch

•

Brand

pinch

: Boyes

: Smith

3

(

)

: _____

Reference

- Chapman's orthopedic surgery
- Campbell's orthopedic surgery
- Encycl. Méd. Chir.

MoKazem.com

- هذه المحاضرة هي من سلسلة محاضرات تم إعدادها و تقديمها من قبل الأطباء المقيمين في شعبة الجراحة العظمية في مشفى دمشق, تحت إشراف د. بشار مير علي.
- الموقع غير مسؤول عن الأخطاء الواردة في هذه المحاضرة.

- This lecture is one of a series of lectures were prepared and presented by residents in the department of orthopedics in Damascus hospital, under the supervision of Dr. Bashar Mirali.
- This site is not responsible of any mistake may exist in this lecture.